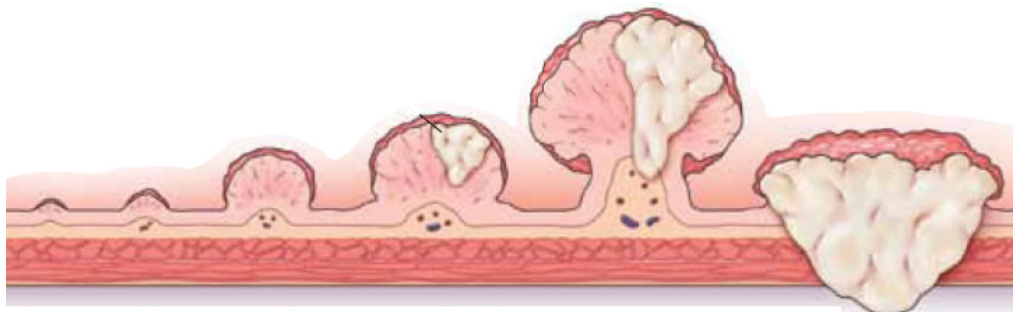





Colorectal Cancer Crossword Puzzle



Across

3. The area of the colon that terminates in the anus and has a higher than average rate of cancer diagnosis.
6. Sacculations in the wall of the colon are:
10. A precancerous growth that can be found during colonoscopy and removed with a snare.
11. This stapler is used for lower anterior colon resections and has "donuts" that are removed after firing.
13. The RNFA must help protect this structure during colorectal surgery and may be stented prior to the procedure.
14. Care must be taken by the RNFA when retracting near the splenic flexure to protect the _____

Down

1. _____'s point is a landmark for appendectomy.
2. A _____ retractor is commonly used for open abdominal cases.
4. Tattooing a polyp can be performed via this procedure.
5. This surgical technique is the approach to open colon resection.
7. The _____ colon is the most mobile part of the large intestine.
8. This blind internal diverticulum is often removed laparoscopically
9. _____ is restoring the continuity of the bowel.
12. The rectum has how many internal infoldings?